

# Male Anatomy

Assigned male at birth

# Testicles:

make sperm and testosterone

# EPIDIDYMISS:

Coils on top of testes where  
sperm go to mature

# Scrotum

Sac of skin that contains the testes

## Testosterone:

A male hormone

# Sperm

Male reproductive cell

# Semen

Mixture of fluid & sperm

# Vas Deferens:

Tube that leads sperm from the testis to the seminal vesicle.

# Seminal Vesicle:

Provides fluid to make the sperm mobile

**Penis:**

**sex organ**

**Glans:**

**sensitive head of the penis**

# ERECTION

Penis becomes filled with blood,  
making it longer and wider

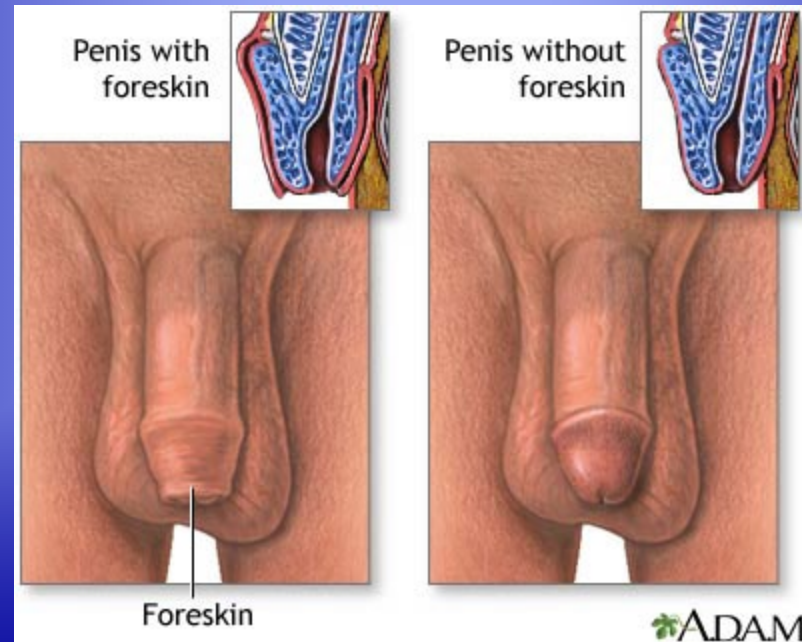


# Foreskin:

skin that covers the glans

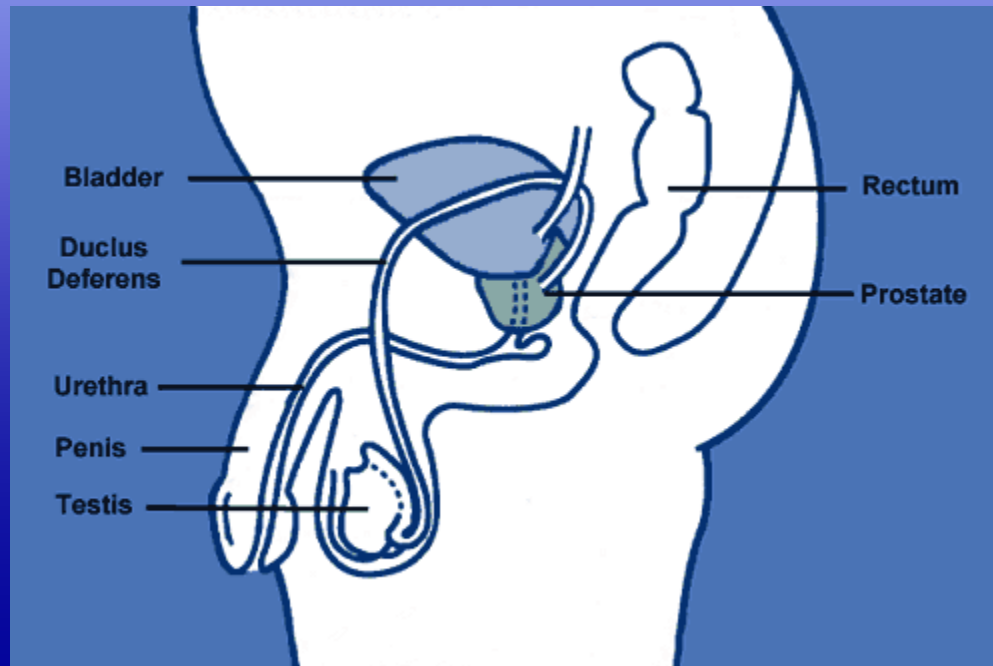
# Circumcision

Surgical removal of the foreskin



# Prostate:

Provides most of the fluid in semen.  
Gland located beneath bladder.



# Urethra:

Tube that carries urine & semen  
out of the body

# Cowper's Glands:

Two very small glands that secrete an alkaline  
fluid to neutralize the acid in the urethra

# EVACULATION

Release of semen  
from the penis

## Nocturnal Emission

when semen leaves the body at night  
(wet dream)

